



**Giant phyllodes tumor: A case report****Tumor filoide gigante. Presentación de un caso****Tumor filode gigante. Apresentação de um caso**Alina Moraga-Rodríguez<sup>1</sup> , Annia Moraga-Rodríguez<sup>1\*</sup> , Alina Rodríguez-Griñán<sup>2</sup> <sup>1</sup>Universidad de Ciencias Médicas de Santiago de Cuba. Santiago de Cuba, Cuba.<sup>2</sup>Hospital Provincial Clínico Quirúrgico Docente "Saturnino Lora Torres". Santiago de Cuba, Cuba.**\*Corresponding author:** [anniamoragarodriguez@gmail.com](mailto:anniamoragarodriguez@gmail.com)**Received:** 08-05-2023 **Accepted:** 11-07-2023 **Published:** 21-07-2023**ABSTRACT**

Giant phyllodes tumors are one of the rarest breast tumors. This tumor typically presents itself as a firm and painless mass, mobile and generally located in one of the breasts. An HIV-positive 17 years old female patient presented a left breast swelling with a history of fast growing pace in the previous 6 months. Physical examination showed an ulcerated painless giant phyllodes tumor on the left breast, with multi-lobed firm characteristics and considerable blood vessel network. The tumor, with a 33cm circumference, took most of the left breast volume. No lymphadenopathies were detected. After radiographic tests, surgical procedure was performed. The anatomopathological report confirmed the presence of a high grade phyllodes tumor. The patient evolved favorably after surgery and was discharged in good general condition, with no fever. The study and management of this pathology was reviewed, as well as the importance of a correct differential diagnosis.

**Keywords:** phyllodes tumor; breast neoplasm; breast; breast cancer**RESUMEN**

Los tumores filoides son una de las tumoraciones raras de la mama. Su forma habitual de presentación es en forma de masa firme, sin dolor, generalmente de un solo lado y móvil. Se presentó el caso de paciente de 17 años, del sexo femenino, con seropositividad para VIH, que se consultó por aumento de volumen de mama izquierda con crecimiento acelerado en los últimos seis meses. Al examen físico se palpó tumoración gigante ulcerada de mama izquierda, indolora y de consistencia firme multilobulada, con red venosa superficial. La tumoración, de unos 33 cm, ocupaba prácticamente toda la mama izquierda. No se palparon adenopatías. Luego de los estudios imaginológicos realizados fue intervenida quirúrgicamente. El estudio anatomopatológico informó tumor filoide de alto grado. La paciente evolucionó favorablemente durante el posoperatorio y se le dio alta médica con buen estado general y sin fiebre. Se revisó el estudio y manejo de esta patología, así como la importancia de un correcto diagnóstico diferencial.

**Palabras clave:** tumorfiloide; neoplasia de mama; mama; cáncer de mama

## RESUMO

Tumores filoides são um dos tumores raros da mama. Sua forma usual de apresentação é como uma massa firme, indolor, geralmente unilateral e móvel. Foi apresentado o caso de uma paciente de 17 anos com soropositividade para HIV, que foi consultada devido ao aumento do volume da mama esquerda com crescimento acelerado nos últimos seis meses. Ao exame físico, palpava-se tumoração gigante ulcerada em mama esquerda, indolor e firme, multilobulada, com rede venosa superficial. O tumor, de cerca de 33 cm, ocupava praticamente toda a mama esquerda. Não havia

adenopatias palpáveis. Após a realização dos exames de imagem, foi submetida a cirurgia. O estudo anatomopatológico relatou um tumor phyllodes de alto grau. A paciente evoluiu bem no pós-operatório, recebendo alta em bom estado geral e sem febre. Foi revisto o estudo e tratamento desta patologia, bem como a importância de um correto diagnóstico diferencial.

**Palavras-chave:** tumor filode; neoplasia da mama; mama; câncer de mama

### How to cite this article:

Moraga-Rodríguez A, Moraga-Rodríguez A, Rodríguez-Griñán A. Giant phyllodes tumor: A case report. Rev InfCient. 2023; 102:4257. DOI: <https://doi.org/10.5281/zenodo.8147704>

## INTRODUCTION

From the Greek term phyllos (leaf), the phylloid tumor (PT) is a fibroepithelial neoplasm that forms in the connective tissue of the breast, presents an intracanalicular architecture, covered by luminal epithelium and is characterized by a stromal hypercellularity.<sup>(1)</sup>

In 1838, Johannes Muller described it as a mixed neoplasm of the mammary gland. It has a large number of clinical forms and biological behavior. Surgical resection is usually the treatment of choice. In this pathology it is rare that both breasts are affected. Of the few cases reported, the two tumors had the same behaviors as benign, malignant or combined.<sup>(2)</sup>

Women between 35 and 55 years of age are the most affected by this type of tumor, with an average age of 45 years. Of primary breast tumors, it represents about 0.3 to 1%. Older women generally present a malignant histology, while in women less than 40 years of age it is less frequent. Women from Asian and Latin American countries are more likely to develop the disease and few cases are diagnosed during gestation.<sup>(3)</sup> The literature does not clearly define risk factors. Li-Fraumeni syndrome, which arises from a mutation of the p53 gene, has been linked to these factors.<sup>(4)</sup>

It presents as a firm, painless, usually one-sided, mobile mass. It may be present in any quadrant of the breast, nipple and ectopic breast tissue. The increase in size may exceed 10 cm in diameter; this affects the anatomy of the gland and ulcers appear at the skin level, however, this does not imply malignancy.

In the skin there may be ischemia due to erosion of the edges and benign volume increases. Intraductal overgrowth or spontaneous ductal transgression may be associated with blood outflow through the nipple. Hypocalcemia is associated with paraneoplastic syndromes.<sup>(5)</sup>



Tumors are classified according to histological characteristics as benign, malignant or borderline. To perform this classification, morphological criteria are taken into account, such as: stromal cellularity, tumor borderline and presence of malignant heterologous elements. In the stroma: presence of cellular atypia, mitotic activity and overgrowth <sup>(6)</sup>.

The theory of pathogenesis is based on epithelial-stromal interactions. The status of resection margins and histologic grade are correlated with local recurrences, which account for 20% of cases. This correlation is higher than with tumor size. Distant metastases can occur in up to 20% of malignant tumors, with the hematogenous route predominating. For patients with these malignant tumors, the 5-year survival rate is 60-80% and 13-40% in patients with metastases. In terms of management and treatment, this tumor represents a challenge because it has a high recurrence rate, corresponding to the large increase in volume and accelerated growth of the lesions.<sup>(7)</sup>

The physical examination is important for the diagnosis of this pathology and complementary studies such as imaging studies, mainly ultrasound in young patients. But the histological study by means of biopsy allows the definitive diagnosis. The conduct to be followed in each case must be assessed individually.<sup>(6)</sup>

## CASE PRESENTATION

A 17-year-old female patient with HIV seropositivity, with a gynecological history, regular menstrual cycle, menarche at 15 years of age, with an increase in volume of the left breast that she noticed growing rapidly in the last six months, for this reason she went for consultation. She was referred for study and treatment.

She presented with a giant ulcerated tumor of the left breast, painless and firm consistency, multilobulated, with accelerated growth and superficial venous network. Tumor occupying practically the entire left breast, about 33 cm, ulcerated at the junction of the lower and outer quadrants, with thinned skin, tension with increased superficial vascularization, erythema and increased local temperature. No adenopathies were found on palpation.

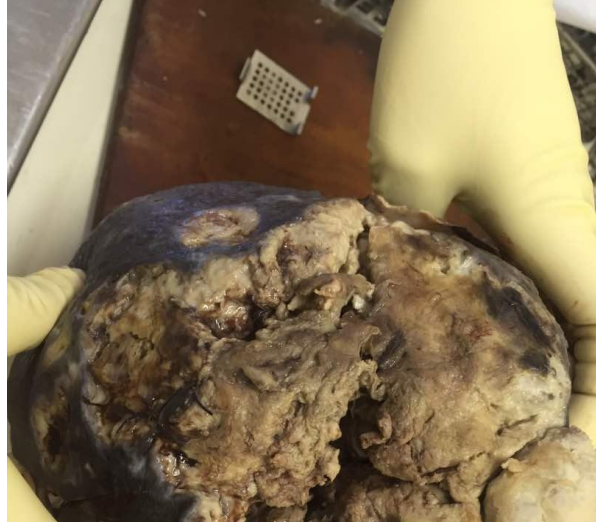Ultrasound of the breast showed a large solid tumor of up to 30×25cm, multilobulated, all four quadrants were occupied, presented great vascularization; liquid areas were observed inside, suggesting necrosis or hemorrhage. It was impossible to perform a mammography due to the characteristics of the tumor.

Abdominal ultrasound was performed, visualizing liver, biliary tract, gall bladder, adrenal glands, spleen and kidneys with normal size and texture. Tumor markers (CEA, CA 15-3) were within normal, as well as hemogram, electrocardiogram and chest X-ray. The left breast incisional biopsy study reported phyllodes breast tumor.

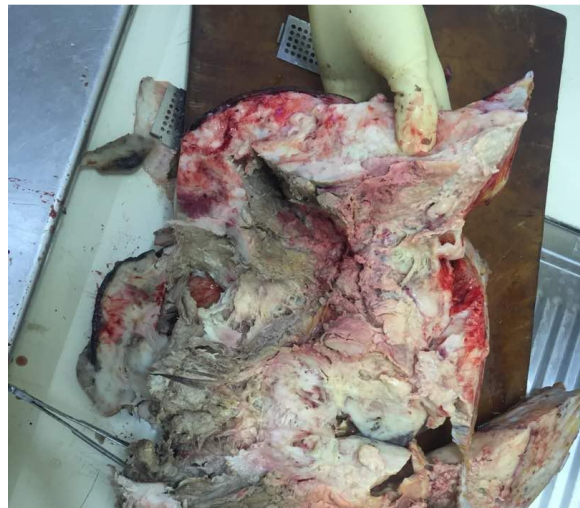With the histological diagnosis, surgical intervention was scheduled. Simple left total mastectomy was performed and then skin grafting was performed.



Macroscopically, the left breast was replaced by an ulcerated tumor mass (Figure 1) measuring 32x20x10 cm (6.5kg in weight), with a whitish-gray fibrous appearance, resembling sarcoma with gelatinous encysted areas. On section, the surface was mucoid, with areas of fleshy hemorrhages and cysts alternating with fibrous areas (Figure 2).



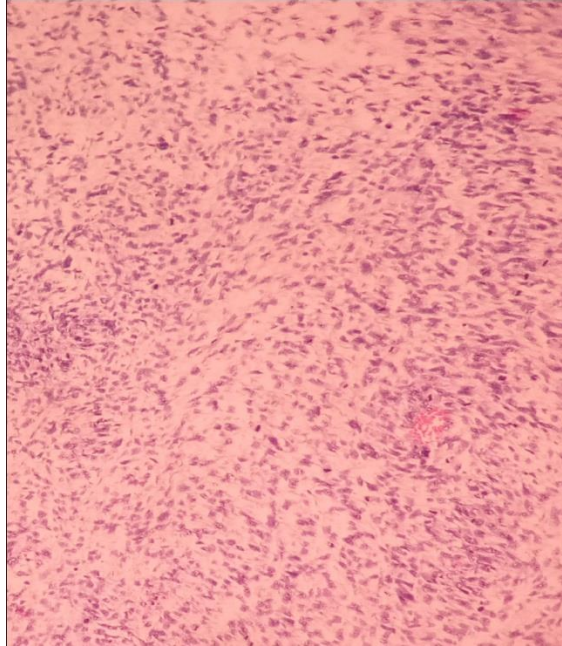
**Figure 1** Giant left breast tumor with necrosis and ulceration.



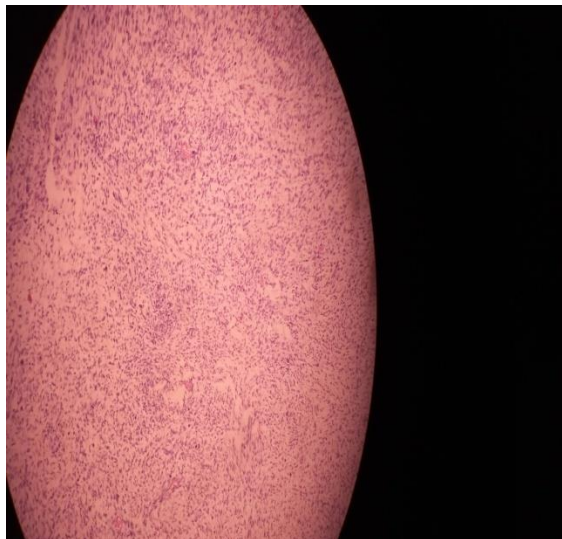**Figure 2** Section cut of breast tumor with areas of hemorrhage.

The anatomopathologic study reported a high phyllodes tumor that respected a deep surgical margin and with presence of ulcer at the epidermis level.

In the histological study only a hypercellular stroma with marked nuclear atypia was observed (Figure 3), mitosis, and the tumor showed only sarcomatous stroma with epithelial elements, mammary ducts (Figure 4). Diagnosis: giant malignant phyllodes tumor.



**Figure 3** sarcomatous stromal tissues



**Figure 4** stromal tissues with presence of mammary ducts in the central portion

The patient evolved favorably during the postoperative period. After 8 days of apyrexia she was discharged with good general condition.



## DISCUSSION OF THE CASE

This neoplasm was initially called cystosarcomaphylloides, later; this term was discontinued because they are not sarcomas according to their biological behavior and cellular origin. It is a biphasic tumor containing stromal and epithelial elements.<sup>(8)</sup>

In the presence of a palpable mass, imaging studies are indicated. In the initial diagnosis mammography is used, where a tumor with defined contours, macrolobulated, reminiscent of a fibroadenoma is visualized. Ultrasound allows classification as a BIRADS IV tumor and the edges of the tumor are smooth, with the presence of intramural cysts and no posterior acoustic enhancement. When necrosis is visualized inside the tumor, it is a sign of malignancy. The use of tomography and magnetic resonance imaging is recommended.<sup>(3,9)</sup>

But these diagnostic means do not allow defining whether it is benign or malignant; therefore a biopsy is necessary, which gives the definitive diagnosis. Thick needles are preferred, since thin needles have a high percentage of false negatives. Microscopically, a slit-like epithelium with a double layer is visualized, surrounding it there is hypercellularstroma protruding from the epithelial lining creating a leaf shape. This tumor has the following features: stromal overgrowth, stromal hypercellularity, amount of stroma relative to the glandular epithelium, nuclear atypia, number of mitoses and infiltrative tumor borders. In fibroadenoma, stromal cellularity is not significant, so it is important for the differential diagnosis of the entity.<sup>(3)</sup>

It is common the use of p63 myoepithelial markers, which as well as cytokeratins (CKs) (CK5/6, 34 $\beta$ E12, cam5.2, CKAE1/AE3) provide negative results in phyllodestumors; this contributes to differentiate them from sarcomas. Progesterone and estrogen receptors do not provide significant results for the stromal component of the pathology.<sup>(5)</sup>

The treatment of choice is surgical, with tumor resection with a border of surrounding tissue of normal appearance of at least 1cm, lymphadenectomy or adjuvant therapies are not used. The most important predictive factor for recurrence is to have a wide tumor-free border (>1cm), therefore the choice of the operative technique must be evaluated for each patient depending on the conditions to achieve this border. Chemotherapy or radiotherapy are used when an adequate surgical margin is not obtained, but no real efficacy has been demonstrated.<sup>(5,10)</sup>

Metastatic dissemination is rare. The hematogenous route is where most metastases occur and they generally affect lung and bone tissue, although some cases of metastasis in liver, skin, brain, thyroid, larynx, pleura, among others, have been reported. When the size of the tumor is greater than 5 cm, continuous follow-up with chest X-ray or CT scan should be performed, as there is an increased risk of metastasis. Mortality occurs in the first three years after diagnosis and survival is short.<sup>(3)</sup>



Recurrences occur in the first two years after treatment, so follow-up with clinical evaluation should be performed twice a year during this period of time and then once a year; mammography should be used every year in patients who did not undergo mastectomy. Recurrence will be related to the nature of the tumor, non-complete excision of the tumor borders and the most aggressive biological type.<sup>(3)</sup>

## REFERENCES

1. Tse GKJTA. Phyllodes tumor. In: International Agency for Research on Cancer. WHO Classification of Tumours. 5ed. Lyon, France: Editorial Board Breast Tumours; 2019. p. 172-6.
2. Cardozo NM, Buhl L, Betancourt Á, Saldivia F. Tumor Filodes Bilateral. A propósito de un caso. Rev Ven Oncol [Internet]. 2021 [cited 12 Jul 2023]; 33(3):155-161. Available at: <https://www.redalyc.org/articulo.oa?id=375666698004>
3. Rockbrand Campos LP, Koutsowris Sáenz S, García Carranza MA, Castro González M, Sibaja Matamorros DA. Tumor Phyllodes: revision de la literatura. Rev Med Legal Costa Rica [Internet]. 2020 Mar [cited 12 Jul 2023]; 37(1):148. Available at: <https://www.scielo.sa.cr/pdf/mlcr/v37n1/2215-5287-mlcr-37-01-146.pdf>
4. Bezerra de Souza Fede Â, Pereira Souza R, Doi M, Brot M de, Bueno de Toledo Osorio CA, Rocha Melo Gondim G, et al. Malignant Phyllodes Tumor of the Breast: A Practice Review. Clin Pract [Internet]. 2021 Apr [cited 12 Jul 2023]; 6; 11(2):205-15. DOI: <https://doi.org/10.3390/clinpract11020030>
5. Frías García-Lago R. Análisis del tratamiento del tumor filodes de mama en la unidad de mama del humv. [Tesis Grado en Medicina]. Santander: Universidad de Cantabria; 2022 jun. [cited 12 Jul 2023]. Available at: [https://repositorio.unican.es/xmlui/bitstream/handle/10902/25748/2022\\_FriasGarciaLagoR.pdf?sequence=1](https://repositorio.unican.es/xmlui/bitstream/handle/10902/25748/2022_FriasGarciaLagoR.pdf?sequence=1)
6. Calderón G, Pajuelo A, Guerra H, De la Cruz M, Hammond R. Tumor Phyllodes de la Mama. Interciencia Méd [Internet]. 2022 [cited 12 Jul 2023]; 12(2):18-25. DOI: <https://doi.org/10.56838/icmed.v12i2.91>
7. Espuelas Malóna S, Nicolau Batalla P, Fabregó Capdevila B, Alcántara da Silva R, Vázquez de las Heras I, Rodríguez Bouzad EM, Vernet Tomása MM. Abordaje multidisciplinar de un tumor phyllodes maligno de mama en una mujer de 16 años. Rev Senol Patol Mama [Internet]. 2020 [cited 12 Jul 2023]; 33(2):72-75. DOI: <https://doi.org/10.1016/j.senol.2020.01.001>
8. Moretti E, Cifuentes X, Falzone S, Ospina M, Godoy A, Lattante R, et al. Citosarcoma filodes maligno. Nuestra experiencia reconstructiva y revisión bibliográfica. Rev Colom Cir Plast Reconst [Internet]. 2021 [cited 12 Jul 2023]; 27(1). Available at: <https://www.ciplastica.com/ojs/index.php/rccp/article/view/166>
9. Gutierrez-Pantoja MA, Arriaga-Piñeiro J, Valdez-Fernández B, Cordido-Henriquez F, Vallejo-Desviat P, Molina-López-Nava P. Lesión bordeline de la mama. Sanid Mil [Internet]. 2021 Sep [cited 26 Abr 2023]; 77(3):156-157. Available at: <https://scielo.isciii.es/pdf/sm/v77n3/1887-8571-sm-77-03-156.pdf>
10. Santos JA, Garcia J, Garcia J, Bonal E, Martin R, Aparicio M. Tumores filoides de la mama: características clínicas en imagen y anatomopatológicas: a propósito de 18 casos. Rev Chil Radiol [Internet]. 2007 [cited 26 Abr 2023]; 13(2):90-97. DOI:



<http://dx.doi.org/10.4067/S0717-93082007000200008>

**Conflict of interest:**

The authors declare that they have no conflicts of interest in the conduct of this work.

**Authors' contribution:**

Conceptualization: Alina Moraga-Rodríguez, Annia Moraga-Rodríguez.

Formal analysis: Annia Moraga-Rodríguez, Alina Rodríguez-Griñán.

Research: Alina Moraga-Rodríguez.

Methodology: Alina Moraga-Rodríguez, Annia Moraga-Rodríguez, Alina Rodríguez-Griñán.

Supervision: Annia Moraga-Rodríguez.

Visualization: Annia Moraga-Rodríguez, Alina Rodríguez-Griñán.

Original drafting and editing: Alina Moraga-Rodríguez, Annia Moraga-Rodríguez, Alina Rodríguez-Griñán.

Writing-revision and editing: Alina Moraga-Rodríguez, Annia Moraga-Rodríguez, Alina Rodríguez-Griñán.

**Financing:**

The authors did not receive funding for the development of the present research.

