




Tibioperoneal syndesmosis: diagnosis, fixation methods and arthroscopy

Sindesmosis tibioperonea: diagnóstico, métodos de fijación y artroscopia

Sindesmose tibiofibular: diagnóstico, métodos de fixação e artroscopia

Alejandro Alvarez-López^{1*} , Valentina Valdebenito-Aceitón^{II} , Sergio Ricardo Soto-Carrasco^{II} 

^I Hospital Pediátrico Provincial Docente "Dr. Eduardo Agramonte Piña". Camagüey, Cuba.

^{II} Universidad Católica de la Santísima Concepción. Facultad de Medicina. Chile.

*Corresponding author: aal.cmw@infomed.sld.cu

Received: 19-12-2022 Accepted: 06-03-2023 Published: 24-03-2023

RESUMEN

Introduction: tibioperoneal syndesmosis injuries are frequent both in isolation or associated with posterior malleolus fractures. Clinical diagnosis is confirmed on imaging studies. Fixation methods might be rigid or dynamic as well. **Objective:** provide new aspects related to tibioperoneal syndesmosis injuries in terms of diagnosis, fixation methods and the use of arthroscopic procedure. **Method:** search and analysis of information needed were carried out in a period of 61 days (from October 1 to November 30, 2022) and the following words were used: syndesmosis injury, ankle syndesmosis instability, syndesmosis instability AND tight rope ankle instability, posterior maleolar fracture. Based on the information obtained, a bibliographic review of the total of 258 articles published in the PubMed, Hinari, SciELO and Medline databases was carried out using the search engine and reference manager EndNote.

Development: it was expressed in the study aspects related to clinical management used in diagnostic and classification on the types of CT scan for fracture associated with posterior malleolar fracture. The rigid and dynamic fixation methods and its characteristics were mentioned as well. The arthroscopic approaches and its advantages for both diagnosis and treatment were presented. **Conclusions:** distal tibioperoneal syndesmosis injuries are frequent ankle injury. Tomographic studies offer some advantages for determining how large the posterior malleolus fracture is. The arthroscopic approach offers multiple diagnostic and therapeutic advantages too.

Keywords: tibioperoneal syndesmosis; computed tomography; fixation methods; ankle arthroscopy

RESUMEN

Introducción: las lesiones de la sindesmosis tibioperonea son frecuentes tanto de forma aislada o asociadas a fracturas del maléolo posterior. El diagnóstico clínico es corroborado mediante estudios imagenológicos. Los métodos de fijación pueden ser rígidos o dinámicos. **Objetivo:** actualizar aspectos sobre las lesiones de la sindesmosis tibioperonea en cuanto al diagnóstico, métodos de fijación y el empleo de la vía artroscópica. **Método:** la búsqueda y análisis de la información se realizó en un periodo de 61 días (1 de octubre al 30 de noviembre de 2022) y se emplearon las siguientes palabras: *syndesmosis injury, ankle syndesmosis instability, syndesmosis instability AND tight rope ankle instability, posterior maleolar fracture*. A partir de la información obtenida se realizó una revisión bibliográfica de un total de 258 artículos publicados en las bases de datos PubMed, Hinari, SciELO y Medline mediante el gestor de búsqueda y administrador de referencias EndNote. **Desarrollo:** se hizo referencia a las maniobras clínicas para el diagnóstico y las clasificaciones tomográficas en caso de fractura asociada del maléolo posterior. Se mencionaron los métodos de fijación rígidos y dinámicos, donde se describieron las características de cada uno basado en varios factores. Se expusieron las ventajas de la vía artroscópica tanto para el diagnóstico como para el tratamiento. **Conclusiones:** las lesiones de la sindesmosis tibioperonea distal son frecuentes. Los estudios tomográficos ofrecen ventajas al determinar la extensión de la fractura del maléolo posterior. La vía artroscópica ofrece múltiples ventajas diagnósticas y terapéuticas.

Palabras clave: sindesmosis tibioperonea; tomografía computadorizada; métodos de fijación; placas y tornillos; artroscopia del tobillo

RESUMO

Introdução: as lesões da sindesmoze tibiofibular são frequentes isoladamente ou associadas a fraturas do maléolo posterior. O diagnóstico clínico é confirmado por exames de imagem. Os métodos de fixação podem ser rígidos ou dinâmicos. **Objetivo:** atualizar aspectos das lesões da sindesmoze tibiofibular quanto ao diagnóstico, métodos de fixação e uso da abordagem artroscópica. **Método:** a busca e análise das informações foi realizada em um período de 61 dias (1º de outubro a 30 de novembro de 2022) e foram utilizadas as seguintes palavras: *syndesmosis injury, ankle syndesmosis instability, syndesmosis instability AND tight rope ankle instability, posterior maleolar fracture*. Com base nas informações obtidas, foi realizada uma revisão bibliográfica de um total de 258 artigos publicados nas bases de dados PubMed, Hinari, SciELO e Medline, utilizando o gerenciador de busca e Gerenciador de referências do EndNote. **Desenvolvimento:** foi feita referência a manobras clínicas para diagnóstico e classificações tomográficas em caso de fractura associada do maléolo posterior. Foram citados métodos de fixação rígidos e dinâmicos, onde foram descritas as características de cada um com base em vários fatores. As vantagens da abordagem artroscópica tanto para o diagnóstico quanto para o tratamento foram discutidas. **Conclusões:** as lesões da sindesmoze tibiofibular distal são frequentes. Os estudos tomográficos oferecem vantagens na determinação da extensão da fratura do maléolo posterior. A abordagem artroscópica oferece múltiplas vantagens diagnósticas e terapêuticas.

Palavras-chave: sindesmoze tibiofibular; tomografia computadorizada; métodos de fixação; placas e parafusos; artroscopia do tornozelo

How to cite this article:

Alvarez-López A, Valdebenito-Aceitón V, Soto-Carrasco SR. Tibioperoneal syndesmosis: diagnosis, fixation methods and arthroscopy. Rev Inf Cient. 2023; 102:e4087. DOI: <https://doi.org/10.5281/zenodo.7768163>



INTRODUCTION

Injuries of the distal tibioperoneal syndesmosis represent 20% of ankle ligament disorders and about 5% require surgery, according to Corte Real and Caetano⁽¹⁾

Hagemeijer, *et al.*⁽²⁾ reports that the incidence of isolated lesion of the distal tibioperoneal syndesmosis is 18%, and 10 to 23% is observed in ankle fractures.

The incidence of ankle fracture according to Xie, *et al.*⁽³⁾, is 112 to 187 cases per 100,000 inhabitants per year and 40% of them affect the posterior malleolus.

These injuries are produced by a mechanism of external rotation and hyperextension of the ankle. The incidence is higher in patients who practice sports. In 20% of the patients, this condition is not diagnosed in the first moments of the trauma. The lack of timely diagnosis leads to the presence of post-traumatic pain, poor functional results, instability, joint stiffness and heterotopic ossification.^(4,5,6)

For the diagnosis of this traumatic entity, clinical and imaging elements are combined; the latter group includes plain radiography, computed tomography, magnetic resonance imaging and high-definition ultrasound.^(7,8,9)

The conservative or surgical treatment modality is based on the degree of instability and associated lesions. The arthroscopic approach is an option of proven efficacy both from the diagnostic and therapeutic point of view.^(10,11,12)

Due to the importance of this topic in traumatology and the scarce information available on this subject in the national literature, a review of this entity was carried out with the aim of updating aspects of tibioperoneal syndesmosis injuries in terms of diagnosis, fixation methods and use of the arthroscopic approach.

METHOD

The search and analysis of the information was carried out over a period of 61 days (October 1 to November 30, 2022) and the following words were used: *syndesmosis injury, ankle syndesmosis instability, syndesmosis instability AND tight rope ankle instability, posterior malleolar fracture*; to focus the search, the Boolean operators OR or AND were used as appropriate.

Based on the information obtained, a bibliographic review of a total of 258 articles published in the PubMed, Hinari, SciELO and Medline databases was carried out using the EndNote search engine and reference manager; of these, 44 selected citations were used to carry out the review, 41 from the last five years.

Review studies, case presentations and original were considered. Researches made in biomechanics laboratories and in animals were excluded.



DEVELOPMENT

The syndesmosis is a complex of anatomical structures composed of the anterior tibioperoneal ligament (ATPL), interosseous ligament, posterior tibioperoneal ligament (PPTL) and the transverse ligament. The LTPP plays the greatest role in stability (it represents 40 to 45%), followed by the LTPA with 35%.^(13,14,15)

The positive diagnosis of this traumatic entity is based on the history of trauma, clinical picture and imaging tests. Patients come to the emergency department with pain and functional impotence of the affected limb. On inspection, an increase in volume above the joint is observed, associated with the presence of hematomas and ecchymosis. In case of fracture, crepitus and abnormal mobility are detected. There are clinical tests that help in the diagnosis of these patients with lesion of the tibioperoneal syndesmosis, such as:^(16,17,18)

- a) Compression test: consists of making compression between the tibia and fibula at mid-leg, if pain appears in the distal tibioperoneal syndesmosis, the test is positive.
- b) Cotton's test: it consists of making compression by the heel and making stress movements from medial to lateral, the presence of pain, displacement greater than 3 mm and snapping translates positivity of the test.
- c) Translation test of the fibula: anteroposterior translation of the fibula is performed, the presence of pain indicates lesion of the tibioperoneal syndesmosis.
- d) External rotation stress test: external rotation of the foot is performed and if pain appears in the anterior tibioperoneal joint, the test is positive. It is considered the most specific test of all.

The most commonly used of images tests are plain radiography, computed tomography, magnetic resonance imaging and high definition ultrasound.^(19,20)

Plain radiography is useful to detect the increase of the tibioperoneal space; this measurement is performed 10 mm proximal to the distal articular surface of the tibia. Anteroposterior and mortise views are performed. Separation greater than 6 mm is suggestive of tibioperoneal injury, as well as decreased peroneotibial overlap, which in the anteroposterior view is less than 6 mm and in the mortise view is less than 1 mm. On occasions, lateral radiography of the ankle does not provide all the information necessary to quantify the displacement of the posterior malleolus, hence the need for other studies with greater precision such as computed tomography.^(21,22)

On the other hand, computed tomography makes it possible to define the extent of the fracture of the posterior malleolus, which plays a very important role in the stability of the tibioperoneal syndesmosis in about 50%. Based on this imaging study, two classifications have been described, the first proposed by Haraguchi, *et al.*⁽²³⁾ and the other by Bartoniček, *et al.*⁽²⁴⁾, which are described below.

Classification by Haraguchi, *et al.*⁽²³⁾ (Figure 1):

- Type I. Fracture with oblique posterolateral fragment (67% incidence, 24% articular surface involvement) (Figure 1A).



- Type II. Fracture with medial extension (19 % incidence, 16 % articular surface involvement) (Figure 2B).
- Type III. Fracture not affecting the articular surface (14% incidence, no articular surface involvement) (Figure 2C).

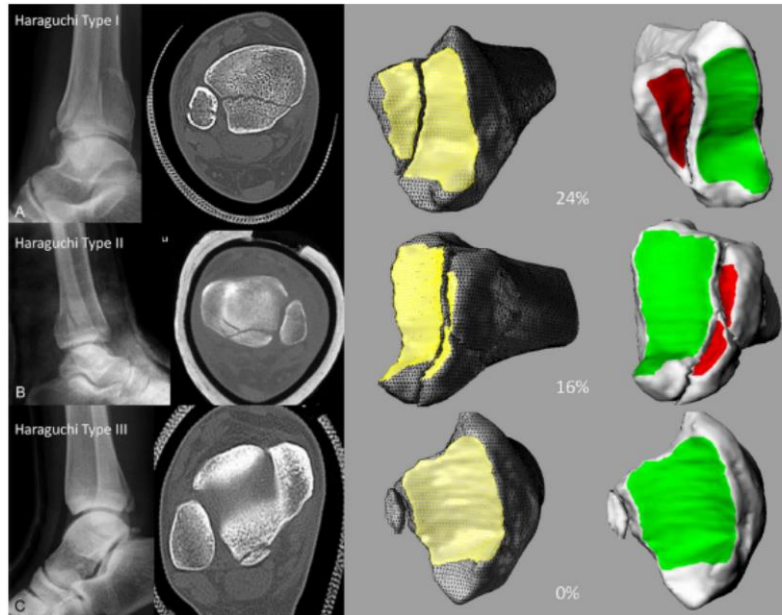


Fig. 1. Classification by Haraguchi, *et al.* **1A.** Fracture Type I. **2B.** Fracture Type II. **2C.** Fracture type III.

Taken from: Haraguchi N, Haruyama H, Toga H. Pathoanatomy of posterior malleolar fractures of the ankle. *J Bone Joint Surg Am.* 2006; 88: 1085-1092. DOI: <https://doi.org/10.2106/jbjs.e.00856>

Bartoníček, *et al.*⁽²⁴⁾ Classification.

It takes into account: size, shape and location of the fragment, stability of the tibiotalar joint and the integrity of the fibula notch; these elements help to define the treatment modality (Figure 2).

- Type 1. Extracisural fragment with intact fibular notch. The fracture is not displaced and, in general, conservative treatment is indicated (Figure 2a).
- Type 2. Posterolateral fragment with extension to the peroneal notch. Open reduction and osteosynthesis from posterior to anterior with plates and screws is required (Figure 2b).
- Type 3. Posteromedial fragment in two parts, reaching the medial malleolus. Open reduction and osteosynthesis from posterior to anterior with plates and screws is indicated (Figure 2c).
- Type 4. Long triangular posterolateral fragment involving more than one third of the articular surface. Requires anterior to posterior or posterolateral screw reduction (Figure 2d).
- Type 5. Irregular fracture with osteoporosis. In this case, lamina and screws should be used.

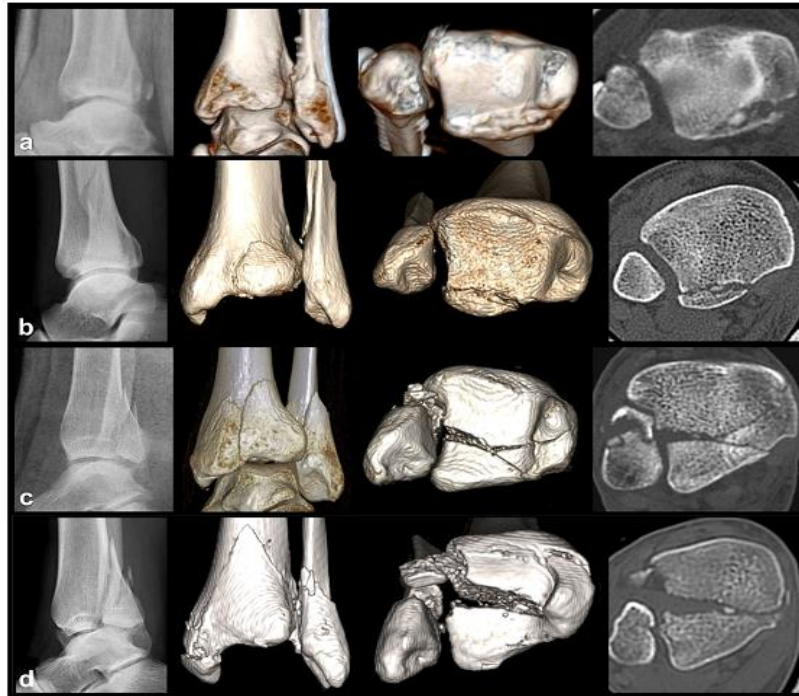

Fig. 2. Bartoníček, et al. Classification 2a. Fracture type 1. 2b. Fracture type 2. 2c. Fracture type 3. 2d. Fracture type 4.

Taken from: Bartoníček J, Rammelt S, Kostlivy, Vaněček V, Klika D, Trešl I. Anatomy and classification of the posterior tibial fragment in ankle fracture. *Arch Orthop Trauma Surg.* 2015; 135: 505-516. DOI: <https://doi.org/10.1007/s00402-015-2171-4>

Magnetic resonance imaging is useful to detect lesions of the ligaments that compose this joint, as well as the presence of osteochondral lesions. However, it has the same disadvantage as the previously described studies (radiography and computed tomography), which are all static. On the other hand, high definition ultrasound does allow, to some extent, the evaluation of the anatomical relationships from the dynamic point of view, as well as the comparison with the healthy extremity.^(8,12,20)

When analyzing the tomographic classifications described above, there are three types of fractures of the posterior malleolus: the first: posterolateral, the second: posteromedial and the third: extra-articular by avulsion. The surgical approach to be used will depend on the displacement of the fragment. If it is posterolateral, it is performed through the interval between the Achilles tendon and the peroneal muscles; if it is posteromedial, it is performed in the interval between the tibia and the posterior tibial tendon.^(20,25)

For the fixation of fractures of the posterior malleolus, screws with or without washers or plates are used depending on the configuration of the fracture, as well as the direction of their placement from anterior to posterior or vice versa. In case of comminution, the placement of plates is justified. Hence, the importance of the CT-based classifications described above.^(26,27,28)

In the surgical treatment of patients with lesions of the tibioperoneal syndesmosis without other associated lesions, different fixation methods can be used, such as screws, with or without blades and the TighRope® technique.^(29,30,31)

The screws to be used for fixation of the distal tibioperoneal syndesmosis are 3.5 mm or 4.5 mm. The use of 3 or 4 cortical fixation has not demonstrated the superiority of one over the other over a period of one year. The minimum placement time is 6 weeks to allow healing of the syndesmosis ligaments. Currently, the use of biodegradable screws eliminates the need for removal of the osteosynthesis device in a second surgical time.^(32,33,34)

There are differences between the TighRope® technique and screw fixation (Table 1).^(35,36,37)

Table 1. Differences between TighRope® and screw fastening methods

Factors	TighRope® Technique	Screws
Type of fixation	Physiological	Rigid
Patients with osteoporosis	Not recommended	Applicable
Age	Young people	Adults
Need for a second intervention	Low	High
Incidence of late diastasis	Low or null	High
Failure due to cyclic loading	Low	High

Source: own elaboration.

The major disadvantages of screw fixation of the tibioperoneal syndesmosis include rigid fixation, the need for a second reintervention and the high possibility of delayed diastasis.^(38,39)

The physiological (dynamic) fixation offered by the TighRope® technique reduces the possibility of post-traumatic arthritis and eliminates the disadvantages of the screw osteosynthesis technique.^(40,41)

The arthroscopic approach makes it possible to confirm the diagnosis statically and dynamically, measure distal tibioperoneal joint separation, detect associated osteochondral lesions, evacuate hemarthrosis, assist in reduction of syndesmosis, posterior malleolus fracture or arthrodesis.

The general advantages of this modality are well known, among which the following stand out: reduction of the postoperative period, rapid incorporation to the rehabilitation process and esthetics. The procedures are generally performed in the anterior chamber of the ankle by means of two or 3 arthroscopic portals.^(42,43,44)

FINAL CONSIDERATIONS

Injuries to the distal tibioperoneal syndesmosis are common. Tomographic studies offer advantages in determining the extent of the posterior malleolus fracture and allow surgical planning. Fractures of the posterior malleolus are unstable when analyzing the anatomical elements. Functional fixation of the syndesmosis offers better results than rigid fixation. The arthroscopic approach offers multiple diagnostic and therapeutic advantages.



REFERENCES

1. Corte-Real N, Caetano J. Ankle and syndesmosis instability: consensus and controversies. *EFORT Open Rev* [Internet]. 2021 Jun [citado 20 Nov 2022]; 6(6):420-431. DOI: <https://doi.org/10.1302/2058-5241.6.210017>
2. Hagemeyer NC, Elghazy MA, Waryasz G, Guss D, DiGiovanni CW, Kerkhoffs GM. Arthroscopic coronal plane syndesmotic instability has been over-diagnosed. *Knee Surg Sports Traumatol Arthrosc* [Internet]. 2021 [citado 20 Nov 2022]; 29:310-323. DOI: <https://doi.org/10.1007/s00167-020-06067-5>
3. Xie W, Lu H, Quan Y, Liu Y, Fu Z, Zhang D, *et al.* Morphological analysis of posterior malleolar fractures with intra-articular impacted fragment in computed tomography scans. *J Orthop Traumatol* [Internet]. 2021 [citado 20 Nov 2022]; 22(1):52. DOI: <https://doi.org/10.1186/s10195-021-00615-6>
4. Baltés TPA, Al-Sayrafi O, Arnáiz J, Al-Naimi MR, Geertsema C, Geertsema L, *et al.* Acute clinical evaluation for syndesmosis injury has high diagnostic value. *Knee Surg Sports Traumatol Arthrosc* [Internet]. 2022 Nov [citado 20 Nov 2022]; 30(11):3871-3880. DOI: <https://doi.org/10.1007/s00167-022-06989-2>
5. Chen KH, Chen CH, Huang YM, Lee HH, Tsuang YH. Injury mechanism affects the stability of suture-button syndesmosis fixation. *J Orthop Surg Res* [Internet]. 2020 Dec [citado 20 Nov 2022]; 15(1):599. DOI: <https://doi.org/10.1186/s13018-020-02141-3>
6. Egol KA, Koval KJ, Zuckerman J. *Handbook of fractures*. 6ed. Philadelphia: Wolter Kluwer; 2020.
7. Chun DI, Cho JH, Min TH, Park SY, Kim KH, Kim JH, *et al.* Diagnostic accuracy of radiologic methods for ankle syndesmosis injury: a systematic review and meta-analysis. *J Clin Med* [Internet]. 2019 Jul [citado 20 Nov 2022]; 8(7):968. DOI: <https://doi.org/10.3390/jcm8070968>
8. Sharif B, Welck M, Saifuddin A. MRI of the distal tibiofibular joint. *Skeletal Radiol* [Internet]. 2020 Jan [citado 20 Nov 2022]; 49(1):1-17. Disponible en: <https://doi.org/10.1007/s00256-019-03260-7>
9. Teramoto A, Shoji H, Anzai K, Kamiya T, Watanabe K, Yamashita T. Tibiofibular space widening assessment with a ball-tipped probe in a syndesmosis injury model. *J Foot Ankle Surg* [Internet]. 2020 Nov-Dec [citado 20 Nov 2022]; 59(6):1215-1218. DOI: <https://doi.org/10.1053/j.jfas.2020.03.024>
10. Hookway S, Lambers A, Page R, Bedi H. The Australian ankle syndesmosis injury survey. *Injury* [Internet]. 2022 Jun [citado 20 Nov 2022]; 53(6):2304-2310. DOI: <https://doi.org/10.1016/j.injury.2022.02.024>
11. Cornu O, Manon J, Tribak K, Putineanu D. Traumatic injuries of the distal tibiofibular syndesmosis. *Orthop Traumatol Surg Res* [Internet]. 2021 Feb [citado 20 Nov 2022]; 107(1S). DOI: <https://doi.org/10.1016/j.otsr.2020.102778>
12. Rudloff MI. Fractures of the lower extremities. En: Azar FM, Beaty JH. *Campbell's Operative Orthopaedics*. 14ed. Philadelphia: Elsevier; 2022. p.2812-2838.
13. Bejarano-Pineda L, Guss D, Waryasz G, DiGiovanni CW, Kwon JY. The syndesmosis, Part I: anatomy, injury mechanism, classification, and diagnosis. *Orthop Clin North Am* [Internet]. 2021 Oct [citado 20 Nov 2022]; 52(4):403-415. DOI: <https://doi.org/10.1016/j.ocl.2021.05.010>
14. Çağlar C, Akçaalan S, Akkaya M. Anatomically fixed posterior malleolar



- fractures in syndesmosis injuries without transsyndesmotoc screw fixation. *Foot Ankle Int* [Internet]. 2022 Apr [citado 20 Nov 2022]; 43(4):486-494. DOI: <https://doi.org/10.1177/10711007211060067>
15. Sin YH, Lui TH. Arthroscopically assisted reduction of sagittal-plane disruption of distal tibiofibular syndesmosis. *Arthrosc Tech* [Internet]. 2019 Apr [citado 20 Nov 2022]; 8(5):E521-E525. DOI: <https://doi.org/10.1016/j.eats.2019.01.014>
16. Pogliacomì F, Filippo M de, Casalini D, Longhi A, Tacci F, Perotta R, *et al.* Acute syndesmotoc injuries in ankle fractures: from diagnosis to treatment and current concepts. *World J Orthop* [Internet]. 2021 May [citado 20 Nov 2022]; 12(5):270-291. DOI: <https://doi.org/10.5312/wjo.v12.i5.270>
17. Spennacchio P, Seil R, Gathen M, Cucchi D. Diagnosing instability of ligamentous syndesmotoc injuries: A biomechanical perspective. *Clin Biomech (Bristol, Avon)* [Internet]. 2021 Apr [citado 20 Nov 2022]; 84:105312. DOI: <https://doi.org/10.1016/j.clinbiomech.2021.105312>
18. Tourné Y, Molinier F, Andrieu M, Porta J, Barbier G. Diagnosis and treatment of tibiofibular syndesmosis lesions. *Orthop Traumatol Surg Res* [Internet]. 2019 Dec [citado 20 Nov 2022]; 105(8S):S275-S286. DOI: <https://doi.org/10.1016/j.otsr.2019.09.014>
19. Yu GS, Lin YB, Xiong GS, Xu HB, Liu YY. Diagnosis and treatment of ankle syndesmosis injuries with associated interosseous membrane injury: a current concept review. *Int Orthop* [Internet]. 2019 Nov [citado 20 Nov 2022]; 43(11):2539-2547. DOI: <https://doi.org/10.1007/s00264-019-04396-w>
20. White T, Bugler K. Ankle fractures. En: *Tornetta P, Ricci WM, Ostrum RF, McQueen MM, McKee MD. Court Brown CM. Rockwood and Green's Fractures in Adults. 9ed. Philadelphia: Wolter Kluwer; 2020.*
21. Williams C, Momenzadeh K, Michalski M, Kwon JY, Nazarian A, Miller CP. Anatomic and radiographic safe zone for posterior malleolar screw placement. *Foot Ankle Int* [Internet]. 2021 Dec [citado 20 Nov 2022]; 42(12):1598-1605. DOI: <https://doi.org/10.1177/10711007211022747>
22. Grambart ST, Prusa RD, Ternent KM. Revision of the chronic syndesmotoc injury. *Clin Podiatr Med Surg* [Internet]. 2020 Jul [citado 20 Nov 2022]; 37(3):577-592. DOI: <https://doi.org/10.1016/j.cpm.2020.03.011>
23. Haraguchi N, Haruyama H, Toga H. Pathoanatomy of posterior malleolar fractures of the ankle. *J Bone Joint Surg Am* [Internet]. 2006 May [citado 20 Nov 2022]; 88(5):1085-1092. DOI: <https://doi.org/10.2106/jbjs.e.00856>
24. Bartoníček J, Rammelt S, Kostlivy, Vaněček V, Klika D, Trešl I. Anatomy and classification of the posterior tibial fragment in ankle fracture. *Arch Orthop Trauma Surg* [Internet]. 2015 Apr [citado 20 Nov 2022]; 135(4):505-516. DOI: <https://doi.org/10.1007/s00402-015-2171-4>
25. Carr JB, Gebhard F. Malleolar fractures and soft tissue injuries of the ankle. En: *Browner BD, Jupiter JB, Krettek C, Anderson PA. Skeletal Trauma. 5ed. Philadelphia: Elsevier; 2015. p.2189-2249.*
26. Baumbach SF, Böcker W, Polzer H. Open reduction and internal fixation of posterior malleolus fractures. *Oper Orthop Traumatol* [Internet]. 2021 Apr [citado 20 Nov 2022]; 33(2):112-124. DOI: <https://doi.org/10.1007/s00064-021-00705-y>
27. Tomar L, Govil G, Dhawan P. Isolated posterior malleolar fracture: a case report of a rare presentation with narrative review of



- literature. *Cureus* [Internet]. 2022 Jan [citado 20 Nov 2022]; 14(1):e21658. DOI: <https://doi.org/10.7759/cureus.21658>
28. Fernández-Rojas E, Herrera-Pérez M, Vilá-Rico J. Posterior malleolar fractures: Indications and surgical approaches. *Rev Esp Cir Ortop Traumatol* [Internet]. 2022 Nov [citado 20 Nov 2022]:160-169. DOI: <https://doi.org/10.1016/j.recot.2022.10.019>
29. Elghazy MA, Hagemeyer NC, Guss D, El-Hawary A, Johnson AH, El-Mowafi H, *et al.* Screw versus suture button in treatment of syndesmosis instability: comparison using weightbearing CT scan. *Foot Ankle Surg* [Internet]. 2021 Apr [citado 20 Nov 2022]; 27(3):285-290. DOI: <https://doi.org/10.1016/j.fas.2021.01.001>
30. Balso C del, Hamam AW, Chohan MBY, Tieszer C, Lawendy AR, Sanders DW. Anatomic repair vs closed reduction of the syndesmosis. *Foot Ankle Int* [Internet]. 2021 Jul [citado 20 Nov 2022]; 42(7):877-885. DOI: <https://doi.org/10.1177/1071100721990008>
31. Kurtoglu A, Kochai A, Inanmaz ME, Sukur E, Keskin D, Türker M, *et al.* A comparison of double single suture-button fixation, suture-button fixation, and screw fixation for ankle syndesmosis injury: a retrospective cohort study. *Medicine (Baltimore)* [Internet]. 2021 Apr [citado 20 Nov 2022]; 100(13):e25328. DOI: <https://doi.org/10.1097/md.00000000000025328>
32. Bafna KR, Jordan R, Yatsosky D, Dick S, Liu J, Ebraheim NA. Revision of syndesmosis screw fixation. *Foot Ankle Spec* [Internet]. 2020 Apr [citado 20 Nov 2022]; 13(2):138-143. DOI: <https://doi.org/10.1177/1938640019843328>
33. Huang CT, Huang PJ, Lu CC, Shih CL, Cheng YM, Chen SJ. Syndesmosis changes before and after syndesmotomic screw removal: a retrospective radiographic study. *Medicina (Kaunas)* [Internet]. 2022 Mar [citado 20 Nov 2022]; 58(3):445. DOI: <https://doi.org/10.3390/medicina58030445>
34. Mercan N, Yildirim A, Dere Y. Biomechanical analysis of tibiofibular syndesmosis injury fixation methods: a finite element analysis. *J Foot Ankle Surg* [Internet]. 2022 May [citado 20 Nov 2022]; 62(1):P107-114. DOI: <https://doi.org/10.1053/j.ifas.2022.05.007>
35. Gan K, Xu D, Hu K, Wu W, Shen Y. Dynamic fixation is superior in terms of clinical outcomes to static fixation in managing distal tibiofibular syndesmosis injury. *Knee Surg Sports Traumatol Arthrosc* [Internet]. 2020 Jan [citado 20 Nov 2022]; 28(1):270-280. DOI: <https://doi.org/10.1007/s00167-019-05659-0>
36. Lehtola R, Leskelä HV, Flinkkilä T, Pakarinen H, Niinimäki J, Savola O, *et al.* Suture button versus syndesmosis screw fixation in pronation-external rotation ankle fractures: a minimum 6-year follow-up of a randomised controlled trial. *Injury* [Internet]. 2021 Oct [citado 20 Nov 2022]; 52(10):P3143-3149. DOI: <https://doi.org/10.1016/j.injury.2021.06.025>
37. Marasco D, Russo J, Izzo A, Vallefucio S, Coppola F, Patel S, *et al.* Static versus dynamic fixation of distal tibiofibular syndesmosis: a systematic review of overlapping meta-analyses. *Knee Surg Sports Traumatol Arthrosc* [Internet]. 2021 Nov [citado 20 Nov 2022]; 29(11):3534-3542. DOI: <https://doi.org/10.1007/s00167-021-06721-6>
38. Yüce A, Misir A, Yerli M, Bayraktar TO, Tekin AÇ, Dedeoglu SS, *et al.* The effect of syndesmotomic screw level on postoperative syndesmosis malreduction. *J Foot Ankle Surg* [Internet]. 2022 May-Jun [citado 20 Nov 2022]; 61(3):P482-485. Disponible en: <https://doi.org/10.1053/j.ifas.2021.09.022>
39. Kaiser PB, Bejarano-Pineda L, Kwon JY, DiGiovanni CW, Guss D. The syndesmosis, Part II: surgical treatment strategies. *Orthop*



- Clin North Am [Internet]. 2021 Oct [citado 20 Nov 2022]; 52(4):417-432. DOI: <https://doi.org/10.1016/j.ocl.2021.05.011>
40. Xu K, Zhang J, Zhang P, Liang Y, Hu JL, Wang X, *et al.* Comparison of suture-button versus syndesmotic screw in the treatment of distal tibiofibular syndesmosis injury: a meta-analysis. J Foot Ankle Surg [Internet]. 2021 May-Jun [citado 20 Nov 2022]; 60(3):P555-566. DOI: <https://doi.org/10.1053/j.ifas.2020.08.005>
41. Xu Y, Kang R, Li M, Li Z, Ma T, Ren C, *et al.* The clinical efficacy of suture-button fixation and trans-syndesmotic screw fixation in the treatment of ankle fracture combined with distal tibiofibular syndesmosis injury: a retrospective study. J Foot Ankle Surg [Internet]. 2022 Jan-Feb [citado 20 Nov 2022]; 61(1):143-148. DOI: <https://doi.org/10.1053/j.ifas.2021.07.009>
42. Taki M, Suzuki K, Yoshimizu T, Hio N, Hasegawa A. Arthroscopic handlebar technique for the treatment of posterior malleolar fractures. J Orthop Sci [Internet]. 2022 Nov [citado 20 Nov 2022]; 27(6):1342-1344. DOI: <https://doi.org/10.1016/j.jos.2022.07.014>
43. Cândido Nishikawa DR, Honda Saito G, Oliveira Junior AS de, Moreira Mendes AA, Piovesana Devito L, Pires Prado M. Clinical outcomes of isolated acute instability of the syndesmosis treated with arthroscopy and percutaneous suture-button fixation. Arch Orthop Trauma Surg [Internet]. 2021 Sep [citado 20 Nov 2022]; 141(9):1567-1574. DOI: <https://doi.org/10.1007/s00402-021-03813-3>
44. Shamrock AG, Khazi ZM, Carender CN, Amendola A, Glass N, Duchman KR. Utilization of arthroscopy during ankle fracture fixation among early career surgeons: an evaluation of the American Board of Orthopaedic Surgery Part II oral examination database. Iowa Orthop J [Internet]. 2022 Jun [citado 20 Nov 2022]; 42(1):103-108. DOI: <https://pubmed.ncbi.nlm.nih.gov/35821943/>

Conflict of interest:

The authors declare that there are no conflicts of interest with respect to this research.

Author contributions:

Conceptualization: Alejandro Alvarez-López, Valentina Valdebenito-Aceitón.

Formal analysis: Alejandro Alvarez-López, Sergio Ricardo Soto-Carrasco.

Investigation: Sergio Ricardo Soto-Carrasco.

Methodology: Alejandro Alvarez-López, Sergio Ricardo Soto-Carrasco.

Project administration: Alejandro Alvarez-López, Valentina Valdebenito-Aceitón,

Supervision: Alejandro Alvarez-López, Sergio Ricardo Soto-Carrasco.

Validation: Alejandro Alvarez-López, Valentina Valdebenito-Aceitón.

Visualization: Alejandro Alvarez-López, Sergio Ricardo Soto-Carrasco.

Writing-original draft: Alejandro Alvarez-López, Valentina Valdebenito-Aceitón, Sergio Ricardo Soto-Carrasco.

Writing-review and editing: Alejandro Alvarez-López, Valentina Valdebenito-Aceitón, Sergio Ricardo Soto-Carrasco.



Funding:

The authors did not receive funding for the development of this article.

